

Vaginal-sparing ventral buccal mucosal graft urethroplasty for female urethral stricture: A novel modification of surgical technique

Nathan Hoag, Johan Gani, Justin Chee

Department of Urology, Austin Hospital, University of Melbourne, Heidelberg, Australia

Purpose: To present a novel modification of surgical technique to treat female urethral stricture (FUS) by a vaginal-sparing ventral buccal mucosal urethroplasty. Recurrent FUS represents an uncommon, though difficult clinical scenario to manage definitively. A variety of surgical techniques have been described to date, yet a lack of consensus on the optimal procedure persists.

Materials and Methods: We present a 51-year-old female with urethral stricture involving the entire urethra. Suspected etiology was iatrogenic from cystoscopy 17 years prior. Since then, the patient had undergone at least 25 formal urethral dilations and periods of self-dilation. In lithotomy position, the urethra was dilated to accommodate forceps, and ventral urethrotomy carried out sharply, exposing a bed of periurethral tissue. Buccal mucosa was harvested, and a ventral inlay technique facilitated by a nasal speculum, was used to place the graft from the proximal urethra/bladder neck to urethral meatus without a vaginal incision. Graft was sutured into place, and urethral Foley catheter inserted.

Results: The vaginal-sparing ventral buccal mucosal graft urethroplasty was deemed successful as of last follow-up. Flexible cystoscopy demonstrated patency of the repair at 6 months. At 10 months of follow-up, the patient was voiding well, with no urinary incontinence. No further interventions have been required.

Conclusions: This case describes a novel modification of surgical technique for performing buccal mucosal urethroplasty for FUS. By avoiding incision of the vaginal mucosa, benefits may include reduced morbidity, urinary incontinence, and wound complications including urethro-vaginal fistula.

Keywords: Buccal mucosa; Female; Reconstructive surgical procedures; Urethral stricture

This is an Open Access article distributed under the terms of the Creative Commons Attribution Non-Commercial License (<http://creativecommons.org/licenses/by-nc/4.0>) which permits unrestricted non-commercial use, distribution, and reproduction in any medium, provided the original work is properly cited.

INTRODUCTION

Female urethral stricture (FUS) represents an uncommon clinical problem, with a paucity of data to guide clinicians on its optimal management. While the causes of FUS may be diverse, commonly cited causes include iatrogenic

injury, trauma, and malignancy [1]. In women with bladder outlet obstruction, the incidence of FUS as the cause has been reported in the range of 4%–13% [2-4]. Symptoms may include frequency, urgency, dysuria, hesitancy, poor stream, incontinence, and recurrent urinary tract infection [5]. Because of overlapping symptoms with other urologic

Received: 17 May, 2016 • **Accepted:** 2 June, 2016

Corresponding Author: Nathan Hoag

Department of Urology, Austin Hospital, University of Melbourne, 145 Studley Rd, Heidelberg, Victoria, 3084, Australia
TEL: +61-3-9496-5000, FAX: +61-3-9428-2234, E-mail: nathanhoag2@gmail.com

conditions, and its rarity, the clinician should have a high degree of suspicion for urethral stricture as a cause of lower urinary tract symptoms in women.

FUS remains without a standardized definition, and studies to date have relied on retrospectively collected data, without uniform methods of collecting and reporting findings [6]. A variety of investigative modalities have been advocated in the work-up of FUS, including: uroflowmetry, measurement of postvoid residual, retrograde urethrogram, voiding cystourethrogram, cystoscopy, and urodynamic studies [7].

Historically a mainstay of management for recurrent FUS, urethral dilation is known to have poor long-term efficacy [8]. The successful management of FUS with long-term clean intermittent catheterization has been reported in a small series [9]. This technique fails to provide a definitive management option, though may be an appropriate option for some.

Osman et al. [6] recently performed a literature review, which examined urethroplasty for FUS. While long-term data is limited, they reported an 80%–94% mean success rate across all techniques.

To date, there is minimal reported evidence for the reconstruction of FUS by ventral buccal mucosal graft urethroplasty. We aim to describe a novel modification of this technique, employing a vaginal-sparing approach.

SURGICAL TECHNIQUE

We present a 51-year-old female with urethral stricture involving the entire urethra. Suspected etiology was iatrogenic from cystoscopy 17 years prior. Since then, the patient had undergone at least 25 formal urethral dilations

and periods of self-dilation. Self-dilation was becoming increasingly difficult, and negatively affecting quality of life. The patient desired a more definitive option and the decision was made to proceed with buccal mucosal graft urethroplasty.

The patient was placed lithotomy position, and the urethra was dilated using Hegar dilators, calibrating to 40 French. Labial retraction sutures were used to aid for optimal exposure. Adequate urethral dilation allows for accommodation of tissue forceps or nasal speculum to facilitate the procedure.

A ventral urethrotomy was carried out sharply using an 11-blade scalpel at the 6 o'clock position, exposing a bed of periurethral tissue (Fig. 1). Care was taken to ensure the incision did not extend to the mucosa, sparing the anterior vaginal wall. It was ensured that this ventral periurethral bed of tissue displayed adequate vascularity, and appeared healthy enough to accommodate placement of a graft.

Buccal mucosa was harvested in a standard fashion from the patient's left cheek [10]. The graft defect was closed with a running suture. An approximately 4 cm by 1 cm strip of buccal mucosa was removed, which was adequate to bridge the length of the urethral defect.

A ventral inlay technique was used to place the graft from the bladder neck to urethral meatus. Three apical bladder neck/proximal urethral sutures (4-0 vicryl) were placed, facilitated by a nasal speculum. Offset needle drivers were used to assist in suture placement. The needle was modified by the surgeon into a "J-shaped" bend, to assist passage [11]. Once the 3 sutures were in place, they were sewn to the corresponding proximal portion of the buccal

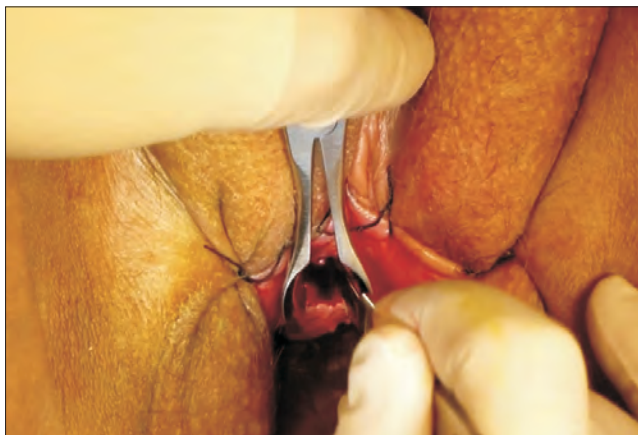


Fig. 1. Intraoperative photograph demonstrating dilated urethra to accommodate nasal speculum, and ventral urethrotomy carried out sharply with 11-blade scalpel.

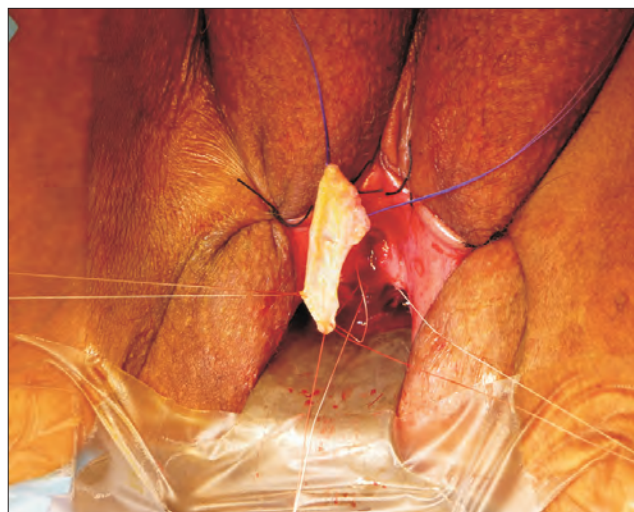


Fig. 2. Intraoperative photograph demonstrating three apical/proximal urethral sutures, sutured to corresponding proximal end of harvested buccal mucosal graft before parachuting into position.

graft, and parachuted into position (Fig. 2). Interrupted 4-0 vicryl sutures were utilized to circumferentially anastomose the graft to the edges of the urethrotomy (Fig. 3). Several interrupted quilting sutures using 5-0 vicryl rapide were placed to secure the graft to its underlying periurethral bed. A 16-Fr urethral Foley catheter inserted.

Operative time was 140 minutes, and estimated blood loss was 50 mL. The patient was discharged home postoperative day 3. Urethral Foley catheter was removed 3 weeks postoperatively for voiding trial. Flexible cystoscopy at 6 months demonstrated patency of the repair. At 10 months of follow-up, the patient was voiding well, with no urinary incontinence. No further interventions have been required.

A complete video overview of the procedure is attached in the supplemental information (Fig. 4; Supplementary video clip).

DISCUSSION

The evolution of reconstructive surgical management for FUS remains relatively recent. The first report of successful vaginal flap reconstruction as an alternative to bladder flap was by Blaivas in 1989 [12]. In 2002, Tanello et al. [13] described the labia minora pedicle flap, while Montorsi et al. [14] reported on vestibular flap urethroplasty for the management of FUS.

There have been subsequent studies examining vaginal flaps using a ventral inlay technique for the management of FUS. While patient numbers were small and studies retrospective in nature, success rates are good, varying between 83%–100% [15,16]. In these procedures, either

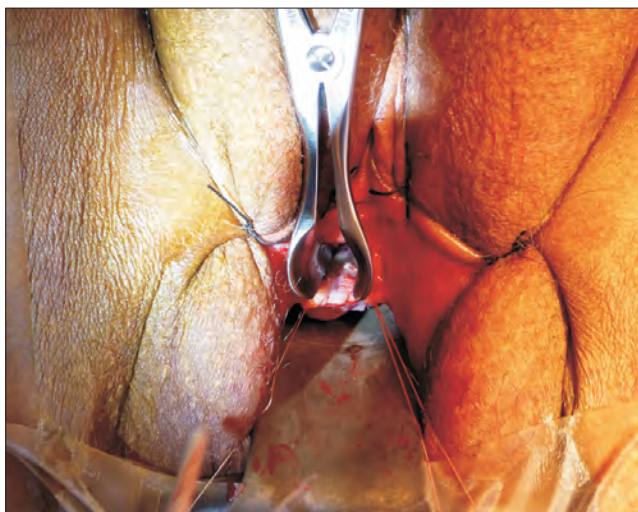


Fig. 3. Intraoperative photograph, with nasal speculum inserted into the urethra, demonstrating ventral placement of buccal mucosal graft, sutured into appropriate position from proximal to distal urethra.

a U-shaped or C-shaped inlay flap was employed with advancement of the flap into a ventral location.

Tsivian and Sidi [17] first described the dorsal onlay graft urethroplasty for FUS, in a series of 3 patients, employing vaginal or buccal mucosal graft. This demonstrated feasibility of this technique, with good functional outcomes.

Subsequent studies have built upon this experience with dorsal onlay buccal mucosal graft urethroplasty with variations in surgical technique. While these studies have been encouraging in their results, their patient numbers remain small, and data retrospective [18-20].

The ventral approach to buccal mucosal graft urethroplasty has been reported by Berglund et al. [21], who noted long-term success in one of 2 women for which the technique was employed. Onol et al. [20] described their technique for ventral onlay buccal mucosal graft urethroplasty in 2 women. They employed a midline vaginal incision to expose the underlying urethra by dissecting free the anterior vaginal wall. They reported excellent results, with the benefit of the option to reinforce the reconstruction with a Martius flap. The rationale for our approach is based on the technique described for male ventral oral mucosal onlay graft urethroplasty, and its associated good results [22].

When compared to the dorsal onlay technique for repair of FUS by buccal mucosal graft urethroplasty, the vaginal sparing approach we utilized has several potential advantages. First, avoidance of dorsal urethral mobilization could reduce postoperative pain. In addition, this technique avoids dissection and possible disruption to the nerve and vascular supply to the clitoris as well as clitoral bulbar tissue, potentially avoiding intraoperative bleeding and postoperative sexual dysfunction.

In comparison to published ventral techniques, the vaginal-sparing modification as described also portends

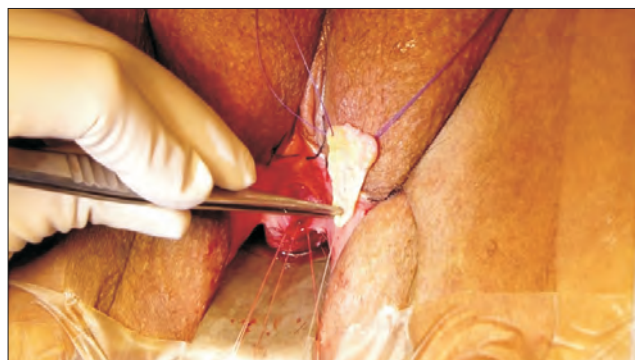

Fig. 4. Video demonstrating vaginal-sparing ventral buccal mucosal graft urethroplasty for female urethral stricture. Scan this QR code to see the accompanying video, or visit www.icurology.org or <https://youtu.be/9s1AzELqJEE>.

some potential benefits. By avoidance of vaginal incision, again postoperative morbidity may be reduced. It may also help to avoid issues of postrative urethrovaginal and vesicovaginal fistula, by circumventing vaginal incision altogether. The vaginal-sparing modification also avoids dissection of the anterior vaginal wall, and could mirror the benefits of the dorsal onlay technique by protecting this tissue for any future anti-incontinence procedure that may be necessary [23]. Compared to the dorsal approach, which requires mobilization of the urethra, the ventral vaginal-sparing approach may avoid division of the pubo-urethral ligament, and potentially reduce the risk of stress urinary incontinence.

Prior anatomic studies have revealed that the striated muscle fibres of the female external urinary sphincter are attenuated in the ventral (or posterior) position, especially in the elderly, and relatively thicker on the dorsal (anterior) aspect [24]. While stress urinary incontinence is rare after urethroplasty for FUS, it remains unknown whether the dorsal or ventral approach would prove a preferential approach from the standpoint of disruption of the external urethral sphincter. Given that the striated muscle is relatively deficient posteriorly, the ventral approach may have a theoretical benefit in this regard.

The disadvantages to this operative technique include the morbidity of buccal mucosal graft harvest, which is avoided in the vaginal flap technique. It is possible that a graft wider than 1 cm may be necessary for severe strictures with a more deficient graft bed. Oral mucosal grafts tend to be well tolerated, however, with minimal morbidity and complications [25]. Also, the lack of long-term follow-up precludes any definitive statement of its continuing efficacy.

While it is clear that no particular technique has demonstrated superiority in the literature to date, the vaginal-sparing modification may prove advantageous.

As methods for definitive reconstruction for FUS continue to evolve, surgeons should continue to innovate and search for the most effective techniques, while aiming to minimize patient morbidity and potential complications. A multidisciplinary approach may be prudent at some centres, as male reconstructive surgeons often has extensive experience harvesting and working with buccal mucosa, while female reconstructive surgeons may tend to be most comfortable with the vaginal anatomy and dissection.

An individualized approach tailoring the most appropriate procedure for a given patient should be advocated. This novel modification of technique may help add to the surgical armamentarium of the reconstructive urologist in managing FUS.

The rarity of FUS contributes to the challenges of conducting larger studies to compare different techniques, and continued academic inquiry into this field will remain important going forward.

CONFLICTS OF INTEREST

The authors have nothing to disclose.

SUPPLEMENTARY MATERIALS

Accompanying videos can be found in the 'Urology in Motion' section of the journal homepage (www.icurology.org). The supplementary video clips can also be accessed by scanning a QR code located on the Fig. 4 of this article, or be available on YouTube (<https://youtu.be/9s1AzELqJEE>).

REFERENCES

1. Faiena I, Koprowski C, Tunuguntla H. Female urethral reconstruction. *J Urol* 2016;195:557-67.
2. Nitti VW, Tu LM, Gitlin J. Diagnosing bladder outlet obstruction in women. *J Urol* 1999;161:1535-40.
3. Groutz A, Blaivas JG, Chaikin DC. Bladder outlet obstruction in women: definition and characteristics. *Neurourol Urodyn* 2000;19:213-20.
4. Kuo HC. Videourodynamic characteristics and lower urinary tract symptoms of female bladder outlet obstruction. *Urology* 2005;66:1005-9.
5. Keegan KA, Nanigian DK, Stone AR. Female urethral stricture disease. *Curr Urol Rep* 2008;9:419-23.
6. Osman NI, Mangera A, Chapple CR. A systematic review of surgical techniques used in the treatment of female urethral stricture. *Eur Urol* 2013;64:965-73.
7. Santucci R, Chen M. Evaluation and treatment of female urethral stricture disease. *Curr Bladder Dysfunct Rep* 2013;8:123-7.
8. Blaivas JG, Santos JA, Tsui JF, Deibert CM, Rutman MP, Purohit RS, et al. Management of urethral stricture in women. *J Urol* 2012;188:1778-82.
9. Smith AL, Ferlise VJ, Rovner ES. Female urethral strictures: successful management with long-term clean intermittent catheterization after urethral dilatation. *BJU Int* 2006;98:96-9.
10. Morey AF, McAninch JW. Technique of harvesting buccal mucosa for urethral reconstruction. *J Urol* 1996;155:1696-7.
11. Barbagli G, Sansalone S, Romano G, Lazzeri M. Ventral onlay oral mucosal graft bulbar urethroplasty. *BJU Int* 2011;108:1218-31.
12. Blaivas JG. Vaginal flap urethral reconstruction: an alternative

- to the bladder flap neourethra. *J Urol* 1989;141:542-5.
13. Tanello M, Frego E, Simeone C, Cosciani Cunico S. Use of pedicle flap from the labia minora for the repair of female urethral strictures. *Urol Int* 2002;69:95-8.
 14. Montorsi F, Salonia A, Centemero A, Guazzoni G, Nava L, Da Pozzo LF, et al. Vestibular flap urethroplasty for strictures of the female urethra. Impact on symptoms and flow patterns. *Urol Int* 2002;69:12-6.
 15. Gormley EA. Vaginal flap urethroplasty for female urethral stricture disease. *Neurourol Urodyn* 2010;29 Suppl 1:S42-5.
 16. Simonato A, Varca V, Esposito M, Carmignani G. Vaginal flap urethroplasty for wide female stricture disease. *J Urol* 2010;184:1381-5.
 17. Tsivian A, Sidi AA. Dorsal graft urethroplasty for female urethral stricture. *J Urol* 2006;176:611-3.
 18. Singh M, Kapoor R, Kapoor D, Kapoor R, Srivastav A, Chipde S. Dorsal onlay vaginal graft urethroplasty for female urethral stricture. *Indian J Urol* 2013;29:124-8.
 19. Sharma GK, Pandey A, Bansal H, Swain S, Das SK, Trivedi S, et al. Dorsal onlay lingual mucosal graft urethroplasty for urethral strictures in women. *BJU Int* 2010;105:1309-12.
 20. Onol FF, Antar B, Kose O, Erdem MR, Onol ŞY. Techniques and results of urethroplasty for female urethral strictures: our experience with 17 patients. *Urology* 2011;77:1318-24.
 21. Berglund RK, Vasavada S, Angermeier K, Rackley R. Buccal mucosa graft urethroplasty for recurrent stricture of female urethra. *Urology* 2006;67:1069-71.
 22. Barbagli G, Montorsi F, Guazzoni G, Larcher A, Fossati N, Sansalone S, et al. Ventral oral mucosal onlay graft urethroplasty in nontraumatic bulbar urethral strictures: surgical technique and multivariable analysis of results in 214 patients. *Eur Urol* 2013;64:440-7.
 23. Migliari R, Leone P, Berdondini E, De Angelis M, Barbagli G, Palminteri E. Dorsal buccal mucosa graft urethroplasty for female urethral strictures. *J Urol* 2006;176(4 Pt 1):1473-6.
 24. Haderer JM, Pannu HK, Genadry R, Hutchins GM. Controversies in female urethral anatomy and their significance for understanding urinary continence: observations and literature review. *Int Urogynecol J Pelvic Floor Dysfunct* 2002;13:236-52.
 25. Barbagli G, Vallasciani S, Romano G, Fabbri F, Guazzoni G, Lazzeri M. Morbidity of oral mucosa graft harvesting from a single cheek. *Eur Urol* 2010;58:33-41.